

Intestinal Neuronal Dysplasia with Intermittent Diarrhea and Pseudo Obstruction

¹Mandana Rafeey, ²Afshin Dezhakam and ³Fatemeh Mahjoub

¹Department of Pediatric Gastroenterology, Liver and Gastrointestinal Diseases Research Center, Tabriz University of Medical Sciences, Tabriz, Iran

²Department of Pediatrics, Tabriz University of Medical Sciences, Tabriz, Iran

³Department of Pathology, Tehran University of Medical Sciences, Tehran, Iran

Abstract: Intestinal Neuronal Dysplasia (IND) is a bowel motility disorder, consisting two distinct clinicopathologic subtypes one manifesting itself as intermittent diarrhea and the other as chronic constipation. We report a patient with intermittent diarrhea and failure to thrive who have a pseudo-obstruction which finally led to the diagnosis of a Intestinal neuronal dysplasia. A review of literature is presented to elucidate the differential diagnosis of the neuronal intestinal dysplasia and pseudo obstruction.

Key words: Neuronal intestinal dysplasia, pseudo obstruction, failure to thrive, malabsorption

INTRODUCTION

Intestinal Neuronal Dysplasia (IND) was first reported by Meier-Ruge in 1971 and then divided into two distinct clinicopathologic entity by Fadda *et al.* (1983). Type A composes the minority of cases and results from a congenital aplasia or hypoplasia of the sympathetic innervations and hence presents acutely in the neonatal period with episodes of intestinal obstruction, diarrhea and bloody stools (Meier-Ruge, 1971; Fadda *et al.*, 1983). Type B resembles Hirschsprung's Disease (HD) and is characterized by malformation of the parasympathetic submucous and myenteric plexuses. The incidence of IND varies from 0.3-40% in different studies (Feldman *et al.*, 2002; Dudley *et al.*, 1958; Ray, 2006).

The main functional pathology is a weak intestinal propulsive motility that can clinically result in delayed meconium passage, constipation, intestinal pseudo-obstruction, or even complete functional intestinal obstruction (Keuzenkamp *et al.*, 1996; Schofield and Yonis, 1991). Although the pathohistologic features of IND B are defined, it is not yet known whether IND B is a malformation of the autonomous intestinal nervous system or an immaturity of the submucous and myenteric plexus because most patients achieve normalization of gut motility with age (Schmittenebecher *et al.*, 2000; Wester *et al.*, 1999; Sacher *et al.*, 1993).

Here, we report a toddler with intermittent diarrhea and failure to thrive whom later was found to have a pseudo-obstruction that finally led to the diagnosis of a Neuronal intestinal dysplasia.

CASE REPORT

A 26-month-old male admitted to hospital due to failure to thrive, recurrent diarrhea and bowel distention. His parents recalled a 7-month history of intermittent diarrhea and constipation that were occasionally foul-smelling and bulky or were associated with blood streaks and mucus. The parents were related. On physical examination, the patient was ill but stable Vital signs. A severe bowel distention was noted. No hepatosplenomegaly or abdominal mass was found. There was also fingers clubbing. Neuromuscular examination was unremarkable.

Initial laboratory findings included a decreased in cholesterol level down to 80 mg dL⁻¹ (normal 140-250), normal liver function tests, normal serum protein and globulin levels with hypophosphatemia of 2 mg dL⁻¹ (normal 4-7). Erythrocyte sedimentation rate: 4 mm h⁻¹. Hemoglobin and hematocrit were 11.2 g dL⁻¹ and 34%, respectively. White blood cell count: 18.9×10³ mm⁻³. Blood urea nitrogen and creatinine were 10 and 0.5 mg dL⁻¹, respectively. Urinalysis was normal. Occult blood and frequent fat droplets was noted on stool examination. Urine and stool culture was unremarkable. Abdominal X-ray showed a long and tortuous sigmoid (dolichosigmoid). A subsequent upper Gastrointestinal (GI) series and abdominal ultrasonography were unremarkable. An upper GI endoscopies was performed which has been showed duodenitis on initial survey.

With a high index of suspicion for celiac disease, the patient was on a trial of a gluten-free diet and discharged

with an scheduled visit to look for any recovery from symptoms. On the follow-up visit, the patient had a moderate improvement with decrease in diarrhea episodes. However, the anti-gliadin and anti-endomysial antibodies were negative (AESKULISA Celicheck, REF 7510 Germany 20 U mL⁻¹ = negative). The gluten-free diet was continued.

Two years later, the patient returned with failure to thrive and repetitive bouts of diarrhea. A mild ascities and pitting edema in lower extremity were finding. Thyroid function tests were normal at this time. Serum IgG, IgA and IgE were 2300 (normal 800-1400), 240 (normal 70-350) and 85 (normal <60), respectively. C3 and C4 and NBT test were normal. Sweat test was negative. Barium enema showed an increased colonic caliber. On an upper GI endoscopy and biopsy, there was a diffuse atrophy and erythema of the gastro-duodenal mucosa. However, no pathologic evidence compatible with celiac disease was seeing. Subsequently, the patient underwent a laparotomy and full thickness biopsy of the stomach. The microscopic inspection of this specimen revealed infiltration of nerve plexuses by mononuclear cells consistent with intestinal inflammatory neuropathy. No evidence Chagas disease detected. Finally, a diagnosis of intestinal pseudo-obstruction due to inflammatory intestinal neuropathy was made and the patient was put on a low fat, low-fiber, high-protein and lactose-free diet. Cisapride, a pro-kinetic agent was also administering at an appropriate dose with controlled QT in ECG and electrolyte and patient followed. Since then, the patient has been admitting several times to receive a total parenteral nutrition and he was follow for 5 years. At this time when he was 6 years old his weight and height were 12 kg and 86 cm, respectively that were both below the fifth percentile of an age-matched controls. Head circumference was 48 cm and at a medium percentile.

DISCUSSION

IND B is a congenital intestinal innervation abnormality of the submucosal autonomic gut innervation. According to the histopathologic criteria described by Meier-Ruge, IND B belongs to the wide spectrum of intestinal dysganglionosis ranging from unclassifiable dysganglionosis, to hypoganglionosis of the myenteric plexus, to minimal changes and immaturity or delayed maturation of intestinal innervation. The histopathologic criteria of IND type B as described by Meier-Ruge include giant ganglia, clusters and heterotopic ganglia cells, increased acetylcholine activity in nerve fibers of the muscularis mucosae and positive

lactate and succinate dehydrogenase staining of the submucous plexus (Meier-Ruge, 1971; Fadda *et al.*, 1983; Feldman *et al.*, 2002; Dudley *et al.*, 1958; Ray, 2006; Keuzenkamp-Jansen *et al.*, 1996; Schofield and Yunis, 1991; Schmittenebecher *et al.*, 2000; Wester *et al.*, 1999; Sacher *et al.*, 1993; Csurly and Pena, 1995).

However, there is still a disagreement on the correlation of histomorphologic intestinal findings, age of onset of symptoms, clinical presentation and suggestions for therapy. Csurly and Pena analyzed publications about IND from Europe and North America and suggested that IND is an ill-defined histology entity with a lack of correlation among histologic findings, symptoms and treatment results. They concluded that IND B represents a wide variety of histopathology changes in bowel innervations (Csurly and Pena, 1995).

Symptoms of pseudo-obstruction usually presents with cramps, stomach pain, nausea and vomiting, bloating, constipation and infrequently loose stools. Pseudo obstruction may be complicated with bacterial infections, malnutrition and muscle problems in other parts of the body. Chronic Intestinal Pseudo-obstruction (CIP) may be due to neuropathy, mesenchymal disease or myopathy. Involvement is mainly colonic in the reported cases. The small bowel is very infrequently affected (Wester *et al.*, 1999; Sacher *et al.*, 1993; Csurly and Pena, 1995).

In the present case the characteristic clinical pattern is the same as another report (Sachvankovsky, 2000; Hyman, 1995). This disease has considerable histological similarity to that of egenerative leiomyopathy. About 10% of infants with CIP improve spontaneously over months or years. For the remaining 90%, there are no cures for the neuromuscular diseases that cause CIP, but there are nutritional, medical and surgical options available to promote normal growth and development. Treatment options include supplemental feeding, total parenteral nutrition, surgery and drug therapy. The responses to cisapride (0.2 mg kg⁻¹ day⁻¹) with out any side effects in our patient similar to other literature (Sachvankovsky, 2000; Dilorenzo, 1999; Whitehead, 2000; Hyman, 1995; Schimple *et al.*, 2004).

It has not yet been clarified whether in IND B surgery (e.g., resection of the affected part of the bowel, sphincteromyectomy, enterostomy, or intensive long-term conservative treatment) are indicated. In the literature, the incidence of surgical treatment is reported in as many as 62% of patients with IND B. However, complete relief of constipation could be obtained in 60 to 70% of patients after a consequent conservative therapy, including diet, repeated enemas, laxatives and prokinetic drug therapy. In

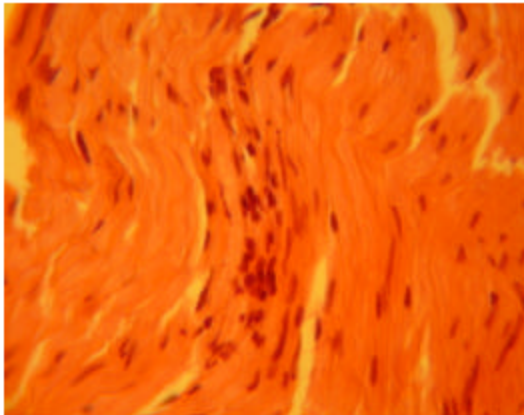


Fig. 1: Intestinal muscle coat and Auerbach's plexus with infiltration of lymphomononuclear cells, obscuring the plexus

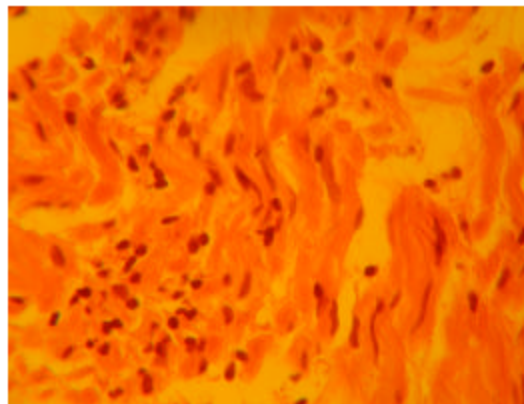


Fig. 2: Closer view of nerve plexus with infiltration of lymphomononuclear cells

younger patients, postponement of surgical therapy has been recommended because a recovery of colon motility within the first 12 months of life has been observed in two thirds of the patients (Schimpe *et al.*, 2004).

In the combination of HD with IND B, the systematic screening for the RET proto-oncogene mutation should be a standard part of the diagnostic and treatment protocol in order to identify the risk of medullary thyroid carcinoma in the preclinical stage of the disease in patients with HD and their relatives. In our patient and relatives we did not found any sign or symptoms of endocrine or proto-oncogene mutation.

Despite the established guidelines for the diagnosis of IND B in mucosal rectal biopsies and the definition of IND B histological criteria, we believe that a definitive

histological diagnosis of the isolated form of IND type B can be diagnosed only from the resected segment of the intestine or a full-thickness biopsy obtained of the specimen (Fig 1 and 2).

CONCLUSION

The present case may aid clinicians in differentiating intestinal malabsorption and motility disorders. The patient in the present case had symptoms of neuronal intestinal dysplasia should be defined, although we did not made specific immunohistochemical staining to investigate the sympathetic affection in this case. In children, clinical presentation related to IND can be treating successfully by conservative treatment regimens, including diet, laxatives and prokinetic drugs.

REFERENCES

- Csury, L. and A. Pena, 1995. Intestinal neuronal dysplasia. Myth or reality? Literature review. *Pediatr. Surg. Int.*, 10: 441-446.
- Dudley, H.A.F., I.S. Sinclair, I.F. McLaren, T.J. McNair and J.E. Newsam, 1958. Intestinal pseudo-obstruction. *J.R. Coll. Surg. Edinb.*, 3: 206-217.
- DiLorenzo, C., 1999. Pseudo-obstruction: Current Approaches. *Gastroenterol.*, 116: 980-987.
- Fadda, B., W.A. Maier and Meier-Uge *et al.*, 1983. Neuronale intestinal Dysplasie: Eine kritische 10-Jahres-Analyse klinischer und biopischer diagnostic. *Z kinderchir.*, 38: 305-312.
- Feldman, M., L.S. Friedman and M.H. Sleisenger, 2002. Sleisenger and Fordtran's Gastrointestinal and Liver Disease: Pathophysiology/Diagnosis/Management. 7th Edn. (2-volume set). St. Louis, MO: Saunders, pp: 2140-2150.
- Hyman, P.E., 1995. Chronic intestinal pseudo-obstruction in childhood: Progress in diagnosis and treatment. *Scand J. Gastroenterol.*, 213: 39-46.
- Keuzenkamp-Jansen, C.W., C.J. Fijnvandraat and C.M.F. Kneepkens *et al.*, 1996. Diagnostic dilemmas and results of treatment for chronic constipation. *Arch Dis Child.* 75: 36-41.
- Meier-Ruge, W., 1971. Uber ein Krankungsbild des colon mit Hirschsprung-Symptomatik. *Vehr. Dtsch. Ges. Pathol.*, 55: 506-510.
- Ray, E., 2006. Intestinal pseudo-obstruction: A diagnostic and therapeutic challenge for the 21 st Century. *Rev. Esp. Enferm. Dig.*, 98: 231-233.
- Schwankovsky, L., 1965. Quality of Life Outcomes in Congenital Chronic Intestinal Pseudo-Obstruction. *Digestive Dis. Sci.*, 47: 1965-1968.

- Schofield, D.E. and E.J. Yunis, 1991. Intestinal neuronal dysplasia. *J. Pediatr. Gastroenterol. Nutr.*, 12: 182-189.
- Sacher, P., J. Briner and B. Hanimann, 1993. Is Neuronal Intestinal Dysplasia (NID) a primary disease or a secondary phenomenon? *Eur. J. Pediatr. Surg.*, 3: 288-230.
- Schmittbecher, P.P., M. Glück and B. Wiebke *et al.*, 2000. Clinical long-term follow-up results in Intestinal Neuronal Dysplasia (IND). *Eur. J. Pediatr. Surg.*, 10: 17-22.
- Schimpl, G., E. Uray, M. Ratschek and M.E. Hollwarth, 2004. Constipation and Intestinal Neuronal Dysplasia Type B: A Clinical Follow-up Study. *J. Pediatr. Gastroenterol. Nutr.*, 38: 308-311.
- Wester, T., D.S. O'Brian and P. Puri, 1999. Notable postnatal alterations in the myenteric plexus of normal human bowel. *Gut*, 44: 666-674.
- Whitehead, W.E., 2000. Gastrointestinal motility disorders of the small intestine and colon. *IFFGD*, 9: No. 4.